

PATIENT

Payton Jung

SPECIES

Canine

BREED

Shetland Sheepdog

SEX

Male Neutered

AGE

14 years

WEIGHT

25.5lbs

INTERPRETED BY

Maggie Machen
 Lamy, DVM, DACVIM
 (Cardiology)

IMAGING PERFORMED BY

Jenna Walsh, CVT

HOSPITAL NAME

VCA Westmoreland
 Animal Hospital

REFERRING VET

Dr. Sullivan

INVOICE

26993

DATE

10/19/22

PRESENTING CLINICAL SIGNS

History: Labored respirations. Heart murmur, grade 4/6. Ataxia. Muscle weakness. Hindlimb conscious proprioception deficit. BP: 147/119(131), 125/81(110), 117/81(96)mmHg.
 -Current medications Nexguard, Cerenia, Furosemide.

RADIOGRAPHIC FINDINGS *NOTE: Images submitted for supplemental cardiac information only.

*Abnormal thoracic anatomy impedes interpretation. Mild cardiomegaly No obvious evidence of CHF.

ELECTROCARDIOGRAPHIC FINDINGS *Note: Single lead ECGs are evaluated as a rhythm strip.

Morphology/MEA cannot be definitively commented on.

A single lead ECG is available; 50mm/s, 20mm/mV. The average heart rate is 110bpm (range 94-136bpm). The rhythm is sinus in origin, with a p for every QRS complex and vice versa. The P and QRS morphologies are positive. No ectopic beats, pauses or dysrhythmias observed.

ECG diagnosis: Normal sinus rhythm with respiratory variation.

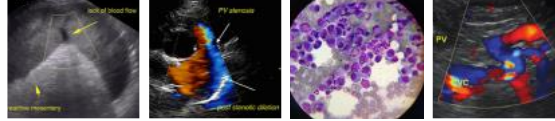
ECHOCARDIOGRAM FINDINGS

2D, m-mode, color flow and doppler imaging is available. Mild diffuse thickening of mitral valve leaflets with minimal prolapse into the left atrial lumen. Mild to moderate mitral regurgitation with minimal left atrial dilation. Normal LV diameter with adequate myocardial function. The tricuspid valve appears mildly thickened with mild to moderate tricuspid regurgitation. Mild right heart enlargement. TR velocity indicative of mild to moderate pulmonary arterial hypertension. The pulmonic and aortic valves are normal in morphology and mobility. Normal pulmonic and aortic outflow velocities with laminar flow. No obvious aortic or pulmonic insufficiency. No pericardial or pleural effusion noted. No obvious cardiac masses.

CARDIAC CHART

CANINE CARDIAC PARAMETERS	MR VMAX (m/s)	TR VMAX (m/s)	LA/AO (Boon method)	LA/AO (Heart Base; Swe)	FS (%)	EF (%)	EPSS (cm)
NORMAL PARAMETER	4.5-5.5	<2.7	1.3	<1.6	28-40	40-100	<0.6
PATIENT	5.3	35	1.1	1.2	38	70	NM
CANINE CARDIAC PARAMETERS	HR (BPM)	AV VMAX (m/s)	PV MAX (m/s)	BODY WEIGHT (kg)	LA 2D short axis Base view (cm)	LVIDd Avg; 2D and m-mode short axis (cm)	LVIDs Avg; 2D and m-mode short axis (cm)
NORMAL PARAMETER	50-100	0.7-1.7	0.7-1.6	BELOW	BELOW	BELOW	BELOW
PATIENT	100	1.1	0.7	11.6	1.7	2.4	1.5
*Normal chamber parameters expressed as a mean value (SD)				3	1.27 (5.3)	2.46 (2.46)	1.36 (5.5)
BODY WEIGHT DEPENDENT PARAMETERS				5	1.40 (4.5)	2.74 (5.2)	1.60 (4.7)
				10	1.50 (3.8)	3.27 (3.5)	2.06 (3.1)
				15	1.83 (2.0)	3.71 (2.4)	2.43 (2.1)
				20	2.02 (1.9)	4.14 (2.2)	2.80 (2.0)
				25	2.18 (2.4)	4.48 (2.9)	3.10 (2.5)

Adapted from June Boon, Veterinary Echocardiography, 1998
 Rishniw M and Hollis NE, J Vet Intern Med 2000; 14:429-435
 Hansson et al, Vet Rad and Ultrasound 2002



PATIENT

Payton Jung

Bonagura et al. Echocardiography: principles of interpretation, Vet Clin North Am 15:1177, 1995	30	2.33 (3.3)	4.83 (3.9)	3.39 (3.4)
	35	2.48 (4.3)	5.17 (5.0)	3.69 (4.5)
	40	2.62 (5.2)	5.48 (6.1)	3.96 (5.4)
	50	2.88 (7.1)	6.07 (8.3)	4.46 (7.4)

SPECIES

Canine

BREED

Shetland Sheepdog

SEX

Male Neutered

AGE

14 years

WEIGHT

25.5lbs

INTERPRETED BY

Maggie Machen
 Lamy, DVM, DACVIM
 (Cardiology)

IMAGING PERFORMED BY

Jenna Walsh, CVT

HOSPITAL NAME

VCA Westmoreland
 Animal Hospital

REFERRING VET

Dr. Sullivan

INVOICE

26993

DATE

10/19/22

INTERPRETATION OF THE FINDINGS & FURTHER RECOMMENDATIONS

Chronic degenerative valve disease causing mild to moderate mitral and tricuspid regurgitation. Lack of significant left atrial enlargement indicates the current risk for complication is low. Mild to moderate pulmonary hypertension is noted, with mild right heart compensatory changes. No concurrent issues such as systolic dysfunction are noted in this study. The ECG is unremarkable with a normal sinus rhythm.

Given these findings, the tachypnea/dyspnea is unlikely to be cardiogenic in origin. Respiratory disease is considered most likely, with pulmonary hypertension developing as a result. A PTE cannot be ruled out. If these symptoms are poorly controlled/progresses long term, this can certainly lead to worsening of PAH. Clinical signs of significant PAH include exertional dyspnea/collapse. Continued monitoring at home is recommended.

In this particular case, given reported tachypnea a trial of Sildenafil can be considered to assess response. Additionally, coverage with a broad-spectrum antibiotic is recommended if the change in breathing was relatively acute onset and pending systemic evaluation. No additional cardiac medications are indicated. This is not expected to explain ataxia/neuro signs, and further systemic evaluation is recommended.

Assessment of progression in the future will help predict long term prognosis, which is highly variable at this stage (B1). Omega fatty acid supplementation and mild salt restriction may be of some long-term benefit. Monitor for development of a cough, labored breathing, exercise intolerance or collapse episodes.

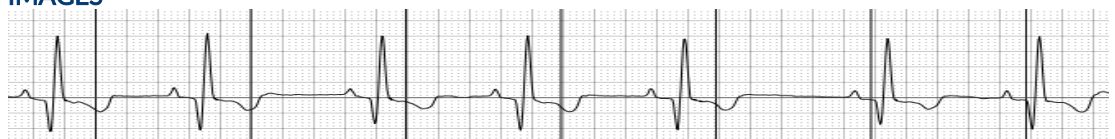Anesthetic risk is considered mild if needed. Cardiac protective drug choices (opioid/benzodiazepine premedication, propofol or alfaxalone induction, isoflurane gas) are recommended. **Pre-oxygenate for 5-10 minutes prior to induction.** Monitor for arrhythmias, hypotension, and hypoxia both intra and post-operatively and intervene as necessary. Mild IV fluid restriction is recommended to avoid fluid overload. Avoid heart rate stimulating drugs such as atropine unless clinically indicated.

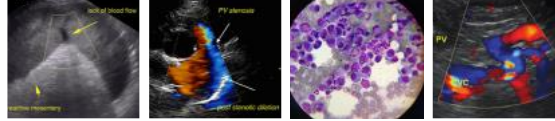
PLAN

No indication for continued Lasix therapy. Consider a Sildenafil trial as discussed: 1-2mg/kg PO q8h and assess response. Recommend broad-spectrum antibiotic coverage for possible respiratory disease if indicated.

Recommend conservative monitoring with a recheck echocardiogram in 6 months, sooner if any recurrence of clinical signs in the interim.

IMAGES





PATIENT

Payton Jung

SPECIES

Canine

BREED

Shetland Sheepdog

SEX

Male Neutered

AGE

14 years

WEIGHT

25.5lbs

INTERPRETED BY

Maggie Machen
Lamy, DVM, DACVIM
(Cardiology)

IMAGING PERFORMED BY

Jenna Walsh, CVT

HOSPITAL NAME

VCA Westmoreland
Animal Hospital

REFERRING VET

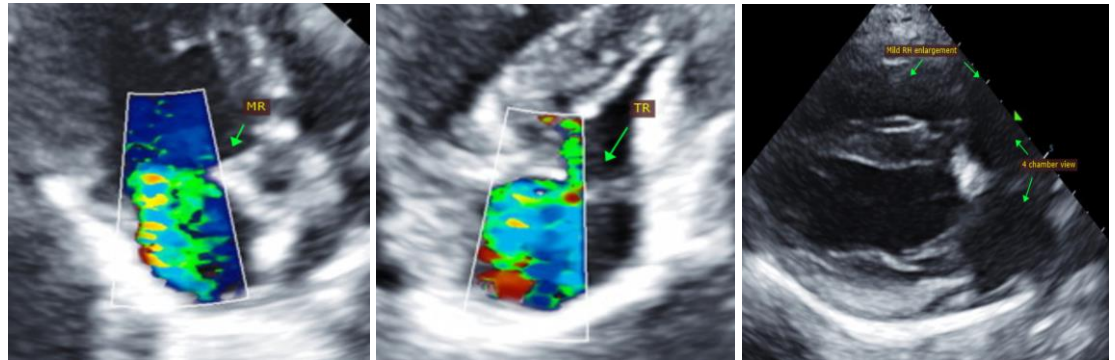
Dr. Sullivan

INVOICE

26993

DATE

10/19/22



The information and recommendations provided are based on the images presented by the referring veterinarian. No evaluation can be communicated regarding pathology that was not visible in the image/video clips provided.

Thank you for this referral. This report was generated using transcription software, and minor dictation errors may be present. If the clinical or image interpretation does not parallel your findings or if I can be of any further assistance, please contact me.

Maggie Machen Lamy, DVM
Diplomate of the American College of Veterinary Internal Medicine (Cardiology)
info@sonopath.com